



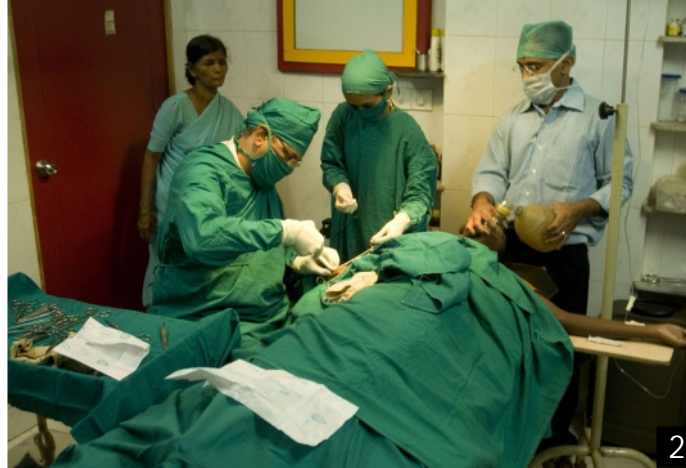Child & Family Welfare Foundation

A Project for the Disabled & Polio Affected

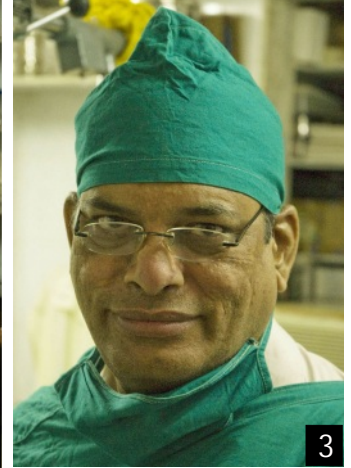The story & treatment of Ashwini Chavan (14), suffering from disability due to Cerebral Palsy!



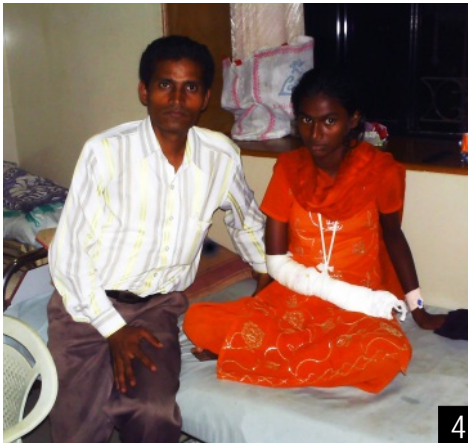1



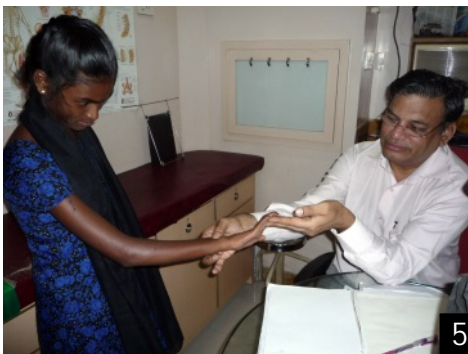2



3



4



5




6



7

Picture-Log:

- 1) Ashwini with her father Bausaheb in their home before treatment.
- 2) The 1st operation being carried out by Dr. Desai and his team.
- 3) Dr. Desai, MSB Ortho. Surgeon, very dedicated to a good cause.
- 4) Bandu with Ashwini during recuperation at the hospital.
- 5) Medical examination by Dr. Desai after completion of the 1st stage.
- 6) CFWF assistant Nisha S. visiting Ashwini with a friend and participant, Mrs. Anita (left). On the right is Ashwini's mother Sushikala.
- 7) Ashwini's progress after completion of half of the treatment.
- 8) CFWF Proj-Manager Josef S. & late Verena S. next to waterpipelines in Ashwini's area, where they started the project 13 years ago!



8

After moving to our new residence we started surveying the very same area for needy, disabled children, where CFWF Project Manager Josef S. with his late wife Verena started the project many, many years ago (see picture #8). Verena, having suffered from cancer, passed on in late 2004. She was instrumental in getting the project started, her dedication and love to care for and look after the Disabled will always be remembered.

In a recent survey we came across an endless line of poorly setup hutments along the wall of a big factory. In one them lives Ashwini, 2nd youngest of a family with five children. They all live in a one-room hutment, are very poor and live well below the poverty level. Her father has presently no work, her mother a part-time job as a sweeper. Ashwini suffers from deformities in her right arm and leg due to Cerebral Palsy. She is amazingly cheerful, despite the difficult living conditions. Ashwini has very little power in her right arm. She could not lift it on her own. At a medical checkup Dr. Desai suggested correctional surgery with Physiotherapy for her right arm and hand.

She first received a 'Release' operation below her right elbow. This was performed well and Ashwini has been doing extensive Physio to bring more muscle power into her arm and hand. She is now able to lift her arm quite a bit on its own without support and has gained a bit more control over the hand movements as well. The progress is slow, but she should be ready for stage II surgery soon. Stage II entails: 1) a 'Wrist-Fusion' surgery, 2) a 'Muscle-Transfer' and an 'Opponan-Plasty' surgery in the thumb of her right hand.

Ashwini has been under regular observation and monthly checkups. Her condition improved to a good degree, but being a Cerebral Palsy case, her progress doesn't come easy, taking patience and regular upkeep with exercises and Physiotherapy. If her treatment ends successfully, relatives of Ashwini's family living close by will send their six year old child, suffering from Polio, for treatment too. We hope for a positive outcome.