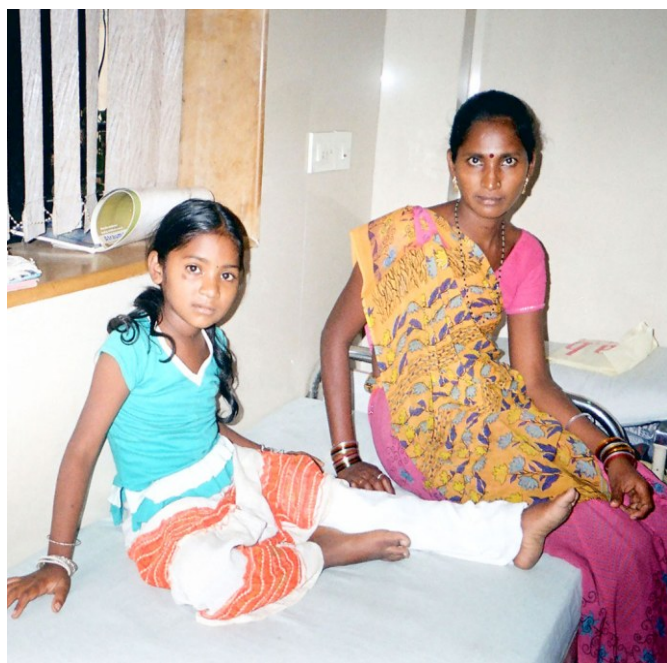


2008-2009 Patients' Treatments and Progress Update (Part II)



Aarti P. Dharoliya, 7 years old patients from Vasai near Mumbai

Aarti is from an area north of Mumbai, where a lot of the labourers live, who work in Mumbai. Housing is cheaper there. Aarti suffers, due to Polio, from a deformity mainly in her right leg. Her right leg is also slightly shorter. She is able to walk, but cannot run. If not attended to, her disability will cause more discomfort with age. The diagnosis by Dr. Desai for Aarti was this: A total of three operations on her right side, hip, knee and foot. The last one is a 'Steindler Plantar Fasciotomy'. Treatment for Aarti started in autumn 2008. All the operations were performed and went well. She responded very positively to the treatment. In the picture to the left is Aarti seen after one of the operations at the hospital with her mother Samrath. Aarti has just completed her treatment, she has gained the desired increase of mobility and stability in her left foot, the shortness has decreased partly too. She will be called for regular checkups about twice a year.



Dipti A. Kamble, 8 years old patient with 'Rickets' disease. Dipti lives in downtown Mumbai with her sisters and parents. She suffers from deformities due to Rickets, also known as Glisson's disease, i.e. Infantile Malacia. Such deformities can in an early infant hood be helped with nutritional correction, i.e. Vit D, E and C. Often, children with minor and moderate deformities will then outgrow the deformities with age. However, due to the severity of Dipti's deformities the degree of her deformity only slightly decreased between age three and seven. Such deformities as hers will not be outgrown by the process of aging. She suffers from deformity in both legs, up and down, which hinders her mobility considerably. Due to this disease her body height is also less than in normal children. She can only wobble around like a baby or a lame duck. At the age of seven she received a free medical checkup, at which time correctional surgery was suggested for her.

PCR-Mumbai is very glad to be able to help Dipti and her family. The operations on both legs were successful and she is doing quite well. Her casts had to be changed once, but the progress is good. In the picture we see Dipti with her mother Ashwira at the hospital recovering from the operations. We visited her and presented her with some children's story books, which Dipti enjoys looking at.



Rijwana Shaikh(24), Polio-patient. In the picture to the left is seen the patient Rijwana Shaikh with PCR volunteer Bandu at the hospital. Rijwana has completed several correctional surgeries. The overall progress has been well. She is still in the recuperation process. Another checkup, after exercising and Physiotherapy, will determine if a new caliper /walking aid will be necessary and beneficial to her.

Visiting Dr. Desai at his clinic. In our regular interaction with Dr Desai and his family we have memorable moments of being together. In the picture are seen (from left): Michelle(13), Nisha and Dr. Desai at the office of his clinic.

